

# Clinical outcomes and rotational stability following implantation of Eyecryl toric intraocular lens – Results of a 12-months prospective study

Sheetal Brar, Mamta Lakhana Shah, Smith Snehal Sute, Savio Pereira, Sri Ganesh

**Purpose:** To evaluate the clinical performance and rotational stability after implantation of Eyecryl Toric monofocal IOL following cataract surgery. **Methods:** Patients undergoing phacoemulsification for age-related cataract and satisfying the eligibility criteria were implanted with Eyecryl Toric IOL. All implantations were done under balanced salt solution. A marker-less system Callisto Eye (Carl Zeiss Meditec, Germany) was used to guide the intra-operative alignment of the toric IOL. **Results:** A total of 50 eyes from 39 patients with mean age of  $68.2 \pm 8.7$  years were included in the study. At 12 months, 82% (41) eyes had cumulative UDVA of 20/20 or better. Post-op SE refraction accuracy was within  $\pm 0.50$  D for 94% ( $n = 47$ ) eyes and refractive cylinder accuracy was within  $\leq 0.50$  D in 98% ( $n = 49$ ) eyes. Average post-op rotation at 1 year was  $4.06 \pm 2.15$  degrees. Eighty-four percent of eyes were within 5 degrees and 16% were within 6-10 degrees of intended axis. Two eyes required IOL re-positioning due to significant rotation of the toric IOL ( $>10$  degrees), identified within the 1<sup>st</sup> week after surgery. **Conclusion:** Eyecryl toric IOL demonstrated the ability to achieve a significant reduction in astigmatism, improved UDVA outcomes, high levels of spectacle independence, low rates of intra-operative injector related complications and good rotational stability at 12 months post-op.

**Key words:** Eyecryl, rotational stability, toric IOL

Various studies have reported that almost 40% eyes have pre-existing corneal astigmatism ranging from 0.75 to  $>3$  D at the time of cataract surgery.<sup>[1]</sup> Residual astigmatism after cataract surgery has been shown to affect the quality of life and reduce patient satisfaction, necessitating its correction with spectacles, limbal relaxing incisions (LRIs) or laser ablative surgery.<sup>[2-6]</sup> These approaches suffer from limitations such as lack of precision, chances of regression, variable healing responses, under-correction/over-correction, loss of best spectacle-corrected visual acuity, risk of infection, and post-operative dry eye.<sup>[2-7]</sup> Also, some patients do not prefer wearing spectacles after cataract surgery. The ability of toric IOLs to treat pre-existing corneal astigmatism along with surgical aphakia, particularly in cases of significant corneal astigmatism was shown to provide a substantial advantage over LRIs, or excimer laser surgery.<sup>[2-6]</sup>

Various toric IOLs evaluated in the past, were shown to successfully reduce ocular astigmatism for safe and effective treatment for cataract patients with corneal astigmatism. Eyecryl Toric IOL (Biotech Vision Care Pvt. Ltd., Ahmedabad, Gujarat, India), is a relatively recent introduction in the field of toric intraocular lenses. The IOL is a single piece, hydrophobic acrylic, aspheric, toric intraocular lens containing natural chromophore, with a 360 degrees square edge. The clinical outcomes with this model of toric IOL have not been evaluated yet. In this study, we report 1-year clinical outcomes in terms of the safety, efficacy,

predictability, rotational stability, complications and overall results with this new toric intraocular lens.

## Methods

This prospective study was approved by the institutional ethics committee of xxxx Eye Hospital, xxxx and adhered to the tenets of the declaration of Helsinki. All patients provided written informed consent.

Inclusion criteria were healthy eyes besides senile cataract; corneal astigmatism equal to or more than 1.0 dioptres (D); IOL powers between +10.00 D and +30.00 D, in the capsular bag IOL implantation. Exclusion criteria were eyes with irregular astigmatism, corneal dystrophy, corneal scar, pupillary abnormalities, history of glaucoma or intraocular inflammation, macular disease or retinopathy, neuro-ophthalmic diseases, and intra-operative or post-operative complications.

Pre-operatively, all patients underwent complete ophthalmologic examination including measurement of uncorrected and best-corrected visual acuity (ETDRS charts, Precision Vision, La Sella, IL, USA), manifest refraction, slit-lamp biomicroscopy, noncontact tonometry (Tomey NCT, NishiKu, Nagoya, Japan), topography using elevation based Scheimpflug

This is an open access journal, and articles are distributed under the terms of the Creative Commons Attribution-NonCommercial-ShareAlike 4.0 License, which allows others to remix, tweak, and build upon the work non-commercially, as long as appropriate credit is given and the new creations are licensed under the identical terms.

**For reprints contact:** WKHLRPMedknow\_reprints@wolterskluwer.com

**Cite this article as:** Brar S, Shah ML, Sute SS, Pereira S, Ganesh S. Clinical outcomes and rotational stability following implantation of Eyecryl toric intraocular lens – Results of a 12-months prospective study. Indian J Ophthalmol 2021;69:1775-80.

### Access this article online

#### Website:

www.ijo.in

#### DOI:

10.4103/ijo.IJO\_3463\_20

### Quick Response Code:



Cataract and Refractive Services, Nethradhama Super Speciality Eye Hospital, Bengaluru, Karnataka, India

**Correspondence to:** Dr. Sheetal Brar, Nethradhama Super Speciality Eye Hospital, 256/14, Kanakapura Main Road, Jayanagar 7<sup>th</sup> Block, Bengaluru, Karnataka, India. E-mail: brar\_sheetal@yahoo.co.in

Received: 19-Nov-2020

Revision: 28-Jan-2021

Accepted: 12-Feb-2021

Published: 18-Jun-2021

imaging device Pentacam HR (Oculus Optikgeräte GmbH, Wetzlar, Germany), specular microscopy (Tomey, Japan), macular OCT (Optovue, Fremont, USA) and dilated fundus examination.

Biometric assessments were performed using the swept-source OCT-based optical biometer, IOL Master-700, and toric IOL power calculations were performed using the Barrett's toric calculator available online at the ASCRS website. All eyes were targeted at emmetropia. An optimized A-constant of 118.7 was used for the toric IOL calculation.

### Description of the study IOL

The Eyecryl Toric IOL (Biotech Vision Care Pvt. Ltd., Ahmedabad Gujarat, India) is a single piece, hydrophobic acrylic, aspheric, toric intraocular lens containing natural chromophore, with a 360 degrees square edge for prevention of posterior capsular opacification [Table 1].

### Surgical procedure

All surgeries were performed by a single experienced surgeon (S.G.), using a standard phacoemulsification technique under topical anaesthesia. All surgeries were performed from the temporal site, through a clear corneal incision of 2.8 mm size, using the Centurion Precision system (Alcon Laboratories, Fort Worth, TX, USA). A standard capsulorhexis of between 5.0 and 5.5 mm was aimed and direct chop technique was used for nuclear deployment. After irrigation and aspiration of the cortex, the left side port was hydrated and BSS injected from the main wound to inflate the bag and form the anterior chamber. Followed by this, the TIOL was carefully injected into the capsular bag using its dedicated injector system (Bio Hydro Cartridge BHC 150 and Bio Hydroject Injector). The co-axial I/A cannula was then introduced to rotate the TIOL into its intended axis. A marker-less system Callisto Eye (Carl Zeiss Meditec, Germany) was used to guide the intra-operative alignment of the toric IOL. Supplementary File 1 shows the surgical video of loading and implantation of an Eyecryl toric IOL, in the right eye of one of the study participants.

Intra-operative complications or a difficulty with IOL injection, if any, was noted. Post-operative topical therapy

included topical prednisolone (1%, Pred Forte, Allergan), moxifloxacin (0.5%, Vigamox, Alcon), and nepafenac (0.1%, Nevanac, Alcon).

Postoperative follow-up examinations were performed at 1 day, 1 week, 2 weeks, 3 months, 6 months, and 12 months after surgery. Dilated slit-lamp examination was performed on post-op day 1 and 1 week to assess the corneal clarity, anterior chamber inflammation and toric IOL position. From 2 weeks onwards, in addition to the above, assessment of manifest refraction, unocular uncorrected and corrected distance visual acuity (UDVA, CDVA), unocular uncorrected and corrected near visual acuity (UNVA, CNVA) and posterior capsule opacification (PCO) was also performed.

Post-operative toric IOL positioning was evaluated by superimposing a grid overlay on the dilated anterior segment photograph taken in retro-illumination using the Eye Cap (Image Capture and Management System, Haag-Streit, USA). Fig. 1 shows the rotational stability of an eye implanted with Eyecryl Toric IOL at 2 weeks and 1 year post-op.

### Statistical analysis

SPSS software for Windows version 17.0.0 (IBM Corp., Armonk, NY) was used for statistical analysis. All values were expressed as mean  $\pm$  standard deviation (SD). Data were checked for normality before subjecting to analysis. A *P* value of 0.05 or less was considered statistically significant. Outcomes analysis was performed according to the Standard Graphs for Reporting Refractive Outcomes Intraocular Lens-Based Refractive Surgery.

### Results

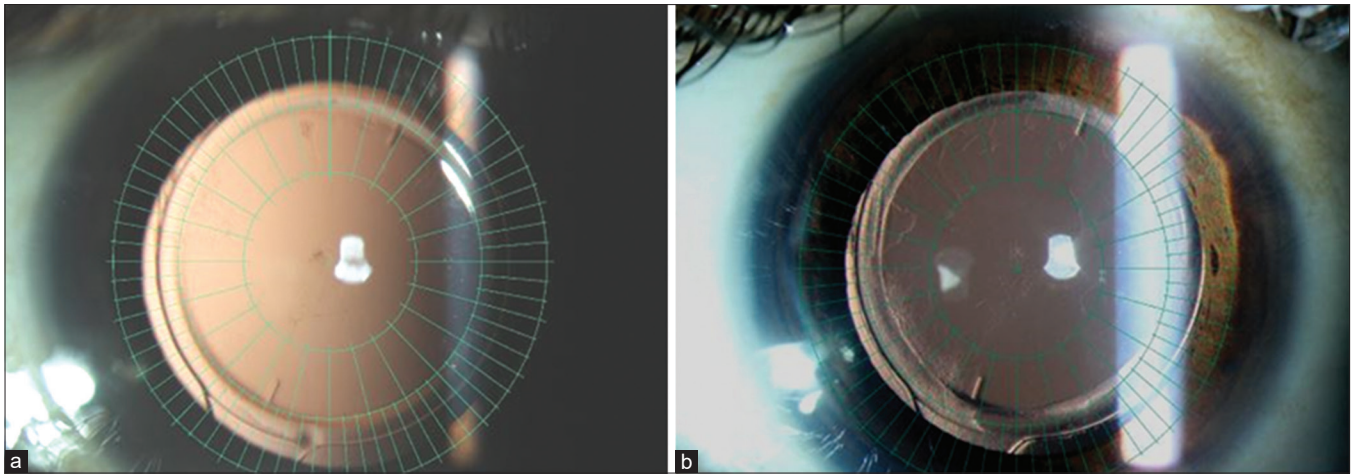
A total of 50 eyes from 39 patients with mean age  $68.2 \pm 8.7$  years, were included in the study. Table 2 shows the preoperative characteristics and demographic data of the study patients.

### Visual outcomes

At 12 months, 82% (41) eyes had cumulative UDVA of 20/20 or better. All (50) eyes had a cumulative UDVA of 20/40 [Fig. 2].

**Table 1: Description of Eyecryl Toric IOL characteristics**

Material	Hydrophobic acrylic containing natural chromophore
Optic type	Single piece, 360° square edge with toric aspheric optic
Optic size	6.00 mm
Haptic design	Optimized C haptic design
Overall size	13.00 mm
Angulation	0 degrees
ACD	5.28 mm
Refractive index	1.48
Dioptr range	+10.00 to + 30.00 D in 0.5 D steps
Cylindrical power options	1.00 D, 1.50 D, 2.25 D, 3.00 D, 3.75 D, 4.50 D, 5.25 D, 6.00 D At corneal plane: 0.68 D, 1.03 D, 1.54 D, 2.05 D, 2.57 D, 3.08 D, 3.60 D, 4.11 D
Recommended range of Corneal Astigmatism	0.25-0.86 D, 0.87-1.25 D, 1.26-1.75 D, 2.26-2.75 D, 2.76-3.25 D, 3.26-3.75 D. 3.76 D and above
Injector	Bio Hydro Cartridge BHC 150 and Bio Hydroject Injector
Implantation site	Capsular bag
Sterilization	Irradiation



**Figure 1:** Representative image showing rotational stability of the study IOL at (a) 2 weeks and (b) 12 months post-operatively

**Table 2: Demographics and baseline pre-operative parameters of all study patients**

Parameter	Mean±SD
Age (years)	68.2±8.7
Male: Female	24:15
K1 (D)	43.15±1.77
K2 (D)	45.22±1.97
Astigmatism (D)	2.07±0.87
Axial length (mm)	23.62±1.19
ECD (cells/mm <sup>2</sup> )	2547.78±277.19
IOL Power (D)	19.83±3.33

K: Keratometry, D: Dioptre, ECD: Endothelial cell density, IOL: Intraocular Lens, SD: Standard Deviation

Twenty-two percent (11) eyes had postoperative CDVA one line or better than the post-operative UDVA, [Fig. 3].

**Refractive outcomes**

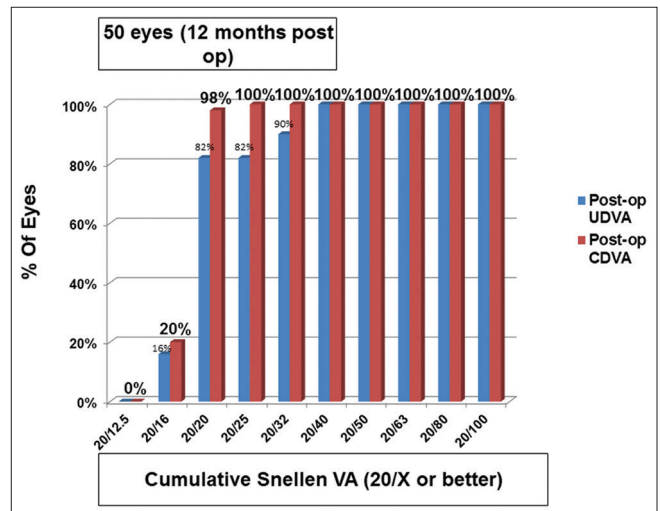
SE refraction accuracy within ± 0.50 D was achieved in 94% (n = 47) eyes and all (50) eyes had SE accuracy within ± 1.00 D, [Fig. 4]. Ninety eight percent (n = 49) eyes achieved refractive astigmatism accuracy within ≤0.50 D, while all (n = 50 eyes) were within ± 1.00 D of post-operative residual cylinder, [Fig. 5].

**Rotational stability**

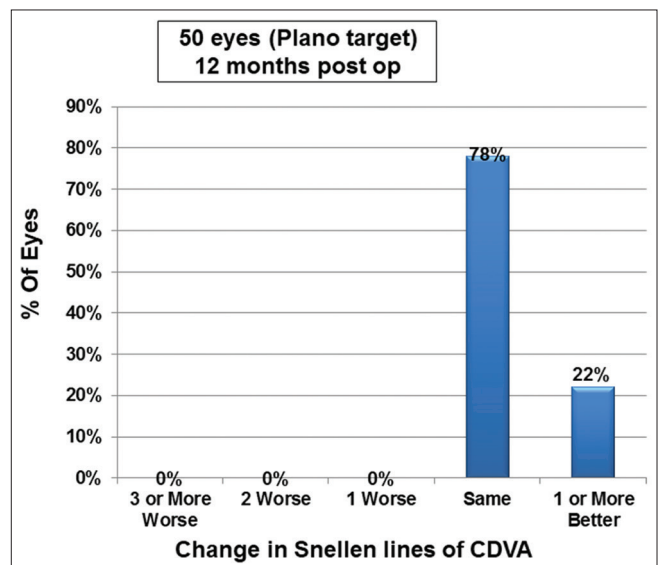
The mean absolute change in axis orientation between visits was less than 3 degrees for all visit intervals. At 1 year, IOL rotation of 5 degrees or less was noted for 84% of eyes. At 1 week, 80% eyes were within 5 degrees, 16% within 6-10 degrees and 4% within 11-15 degrees of intended axis. On the last follow up at 12 months, however, 84% eyes were within 5 degrees and 16% were within 6-10 degrees of intended axis, [Fig. 6]. Table 3 shows the visual outcomes and rotational stability at various post-op visits. There was no significant change in the rotation values over time. Average post-op rotation at 1 year was 4.06 ± 2.15 degrees, which was not statistically different from 2 weeks value of 3.98 ± 2.15 degrees (P = 0.99).

**Complications and re-surgery**

Intra-operatively, all IOL implantations were smooth and there was no incidence of optic -haptic adhesions, haptic



**Figure 2:** Histogram showing, UDVA and CDVA for the study IOL at 12 months post-operatively



**Figure 3:** Histogram showing the change in Snellen's lines of CDVA



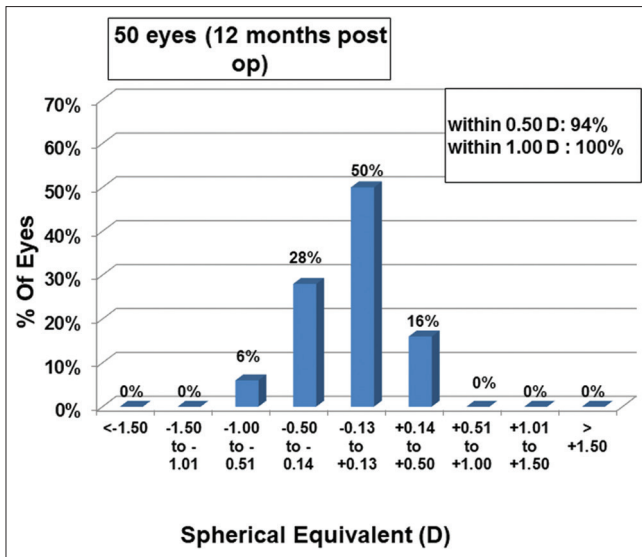


Figure 4: Histogram showing the accuracy to the intended spherical equivalent refraction at 12 months post-op

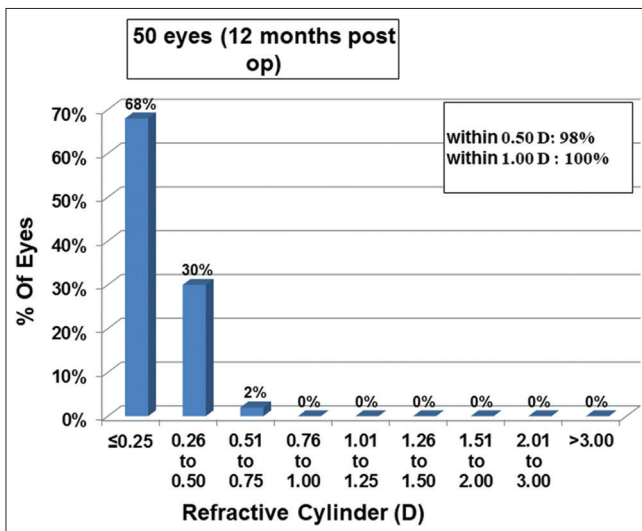


Figure 5: Histogram showing change in refractive astigmatism at 12 months post-op

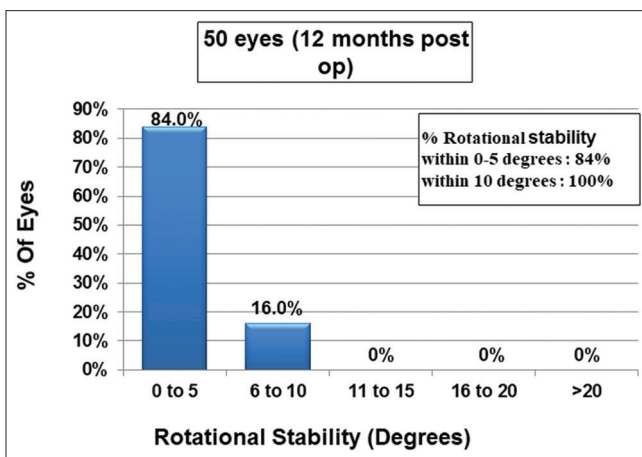


Figure 6: Histogram showing rotational stability of study IOL at 12 months post-op

breakage/tear, or IOL stuck inside the wound. No postoperative complications such as cystoid macular oedema, post-op uveitis, secondary glaucoma or posterior capsule opacification requiring YAG- Capsulotomy were noted in any of the eyes. No IOL required exchange or explantation due to any reason.

Two eyes required IOL re-positioning due to significant rotation of the toric IOL (>10 degrees), identified within the 1<sup>st</sup> week after surgery. Both IOLs were re-positioned on the same day, after which they remained stable at the subsequent visits.

### Discussion

Kim *et al.*<sup>[8]</sup> evaluated the long-term efficacy and rotational stability of the AcrySof toric intraocular lens (IOL) in correcting preoperative astigmatism in cataract patients. At the final follow-up of 13.3 ± 5 months, mean refractive astigmatism reduced to -0.28 ± 0.38 D from -1.28 ± 0.48 D, and the mean rotation of the toric IOL was 3.45 ± 3.39 degrees. One eye (3.3%) exhibited IOL rotation of 10.3 degrees, the remaining eyes (96.7%) had IOL rotation of less than 10 degrees. The study concluded that implantation of the AcrySof toric IOL was an effective, safe, and predictable method for managing corneal astigmatism in cataract patients both in the early and long-term follow-up. Compared to this study, we observed better post-op predictability as the residual cylinder in our study was -0.14 D, at a similar mean follow-up (12 months).

Waltz *et al.*<sup>[9]</sup> recently evaluated the safety and effectiveness of the TECNIS toric intraocular lenses (IOLs) in a prospective, multicentric, 2-armed, bilateral, 6-clinical trial. They found that lens rotation of 5 degrees or less occurred in 92.9% of toric eyes between 1 and 3 months and in 94.1% between 3 and 6 months, exceeding the ANSI standard for stability (90% of eyes within 5 degrees of rotation between visits). Four lenses (2.3%) were repositioned during the study. In the present study, an IOL rotation of 5 degrees or less was noted for all (100%) eyes at 6 months compared to 3 months, exceeding the requirement for lens stability defined in the ANSI standard for toric IOLs with 90% or more of lenses rotating 5 degrees or less between visits approximately 3 months apart.<sup>[8]</sup> Even after 6 months, no significant rotations were observed until the end of the mean follow-up.

The main issue with the toric IOLs is their postoperative rotation. Correct toric lens positioning is very important because it was shown in different studies that a rotation of 10 degrees from the target axis could result in a loss of more than 30% of the effectiveness of a toric IOL.<sup>[10-13]</sup> Therefore, there are several IOL alignment methods, including manual marking, iris-finger printing technique, intra-operative wavefront aberrometry, and automated intra-operative registration systems, such as the investigated system, or the Verion system (Alcon Laboratories, Inc.).<sup>[14-16]</sup>

Corneal marking has several disadvantages and can lead to post-operative toric intraocular lens (IOL) misalignment, which can cause a loss of effectiveness of the toric IOL.<sup>[17]</sup> In a recent study by Varsits *et al.*, the authors evaluated the CALLISTO eye software, which is an intraoperative toric intraocular lens alignment system with an image-guided system.<sup>[18]</sup> They concluded that it was an accurate and fast procedure resulting in precise toric IOL alignment and simplified the positioning of toric IOLs. In the present study as well, this tool was found

**Table 3: Visual and refractive outcomes at 2 weeks, 3 months, 6 months and 12 months post-op**

Parameter (Mean±SD)	2 weeks	3 months	6 months	1 year	P
UDVA (LogMAR)	0.08±0.09	0.07±0.09	0.04±0.15	0.03±0.17	0.07
CDVA (LogMAR)	0.01±0.06	0.01±0.05	-0.00±0.07	-0.02±0.04	0.09
Sph (D)	-0.09±0.29	-0.10±0.29	-0.11±0.29	-0.11±0.29	0.99
Cyl (D)	-0.12±0.32	-0.13±0.32	-0.13±0.31	-0.14±0.30	0.99
SE (D)	-0.16±0.34	-0.17±0.35	-0.17±0.34	-0.18±0.33	0.99
IOL rotation (°)	3.98±2.15	4.00±2.14	4.02±2.11	4.06±2.15	0.99

UDVA: Uncorrected distance visual acuity, CDVA: Corrected distance visual acuity, Sph: Sphere, Cyl: Cylinder, SE: Spherical equivalent; D: Dioptre, IOL: Intraocular Lens

to facilitate hassle free implantation of the toric IOL, obviating the need of pre-operative corneal marking and resulted in a high level of accuracy in IOL positioning.

In the context of post-op stability, IOL haptic design is crucial for maintaining axial and rotational stability of the IOL. While the study by Patel *et al.*<sup>[19]</sup> reported plate haptic IOL to be more stable, the study by Prinz *et al.*<sup>[20]</sup> showed no significant difference between the two IOL designs but they were based on previous IOL designs. In this context, the “optimized C haptic design”<sup>[21]</sup> of Eyecryl toric IOL haptics, appears to provide good stability in the capsular bag, which may explain the fact that there was no significant difference observed between post-op rotation values at 12 months, compared to those at 2 weeks.

As shown in various studies, the postoperative rotation is seen more in early postoperative period, as early as 1 hour after the surgery.<sup>[15,18]</sup> The previously mentioned study by Varsits *et al.*<sup>[18]</sup> noted that the mean absolute difference between the photographs from 1 hour postoperatively and the preoperatively aimed toric IOL axis was 4.45 degrees (range 0.35 to 19.46 degrees). Webers *et al.*<sup>[15]</sup> also performed their first measurements for IOL misalignment 1 hour after surgery with misalignment to the aimed toric axis. At the 1-week, 1-month, and 3-measurement points, however, no significant differences were seen. This is the reason why we performed an additional post-operative check-up at 1-week post-op, as toric IOL position usually settles by this time and rotations, if any, can be diagnosed and managed easily. In the immediate post-op period, sometimes wound or corneal oedema may preclude the precise evaluation of the toric IOL axis. At 1 week, usually the wound and corneal oedema, and anterior chamber inflammation resolves, making the assessment of post-op toric IOL axis and refraction more accurate and predictable. In case of significant rotation, it is still convenient to align the IOL back into its correct position, as the IOL-bag adhesions are not very strong compared to when it is at 2 weeks or more, wherein capsular adhesions with the IOL may preclude safe manipulation of the toric lens.

Retained ophthalmic visco-surgical device (OVD) has been implicated as one of the most common causes of post-op rotation of a toric IOL.<sup>[22]</sup> The low incidence of post-op rotation of the toric IOL seen in our study could also be attributed to the fact that all implantations were performed under balanced salt solution. By avoiding the use of an OVD during the implantation, the chances of OVD retention are expected to minimise, potentially reducing the incidence of toric IOL rotation in the post-operative period. The two eyes requiring re-positioning were myopic eyes (IOL

powers +18.00 and 18.50 D), which could be a potential contributing factor leading to post-op rotation of the toric IOL due to relatively large bag size, as suggested by various studies.<sup>[23,24]</sup>

In the present study, Barrett Toric calculator was used for treatment planning, as it is based on the Barrett’s Universal II formula and predicted corneal curvature. The formula has shown to yield lower astigmatic prediction errors compared to a standard toric calculator based on anterior keratometry data only in recent studies.<sup>[25]</sup>

No significant differences in the mean values of post op rotation were observed between 2 weeks and 12 months. This may be explained by the fact that various studies have shown that the chances of IOL rotation decrease as there is fusion of the anterior and posterior capsules, which starts as early as 2 weeks post-op. Toric IOL rotation is rarely seen after 3 months.<sup>[26]</sup>

## Conclusion

In conclusion, the Eyecryl toric IOLs demonstrated the ability to achieve significant reductions in astigmatism, improved UDVA outcomes, high levels of spectacle independence, low rates of intra-operative injector related complications and good rotational stability at 1-year post-op. To our knowledge, this is the first study reporting the clinical outcomes with the Eyecryl toric IOLs, showing good safety and efficacy for treatment of cataract with astigmatic eyes. However, further data and longer follow-ups are suggested to establish the long-term effect on rotational stability, PCO formation and changes in post-op refraction.

## Financial support and sponsorship

Dr Sri Ganesh and Dr Sheetal Brar are consultants to Biotech Vision Care Pvt Ltd.

## Conflicts of interest

There are no conflicts of interest.

## References

1. Prasher P, Sandhu JS. Prevalence of corneal astigmatism before cataract surgery in Indian population. *Int Ophthalmol* 2017;37:683-9.
2. Fan YY, Sun CC, Chen HC, Ma DH. Photorefractive keratectomy for correcting residual refractive error following cataract surgery with premium intraocular lens implantation. *Taiwan J Ophthalmol* 2018;8:149-58.
3. Lam DK, Chow VW, Ye C, Ng PK, Wang Z, Jhanji V. Comparative evaluation of aspheric toric intraocular lens implantation and limbal relaxing incisions in eyes with cataracts and  $\leq 3$  dioptres of

- astigmatism. *Br J Ophthalmol* 2016;100:258-62.
4. Lake JC, Victor G, Clare G, Porfirio GJ, Kernohan A, Evans JR. Toric intraocular lens versus limbal relaxing incisions for corneal astigmatism after phacoemulsification. *Cochrane Database Syst Rev* 2019;12:CD012801. doi: 10.1002/14651858.CD012801.pub2.
  5. Nagpal R, Sharma N, Vasavada V, Maharana PK, Titiyal JS, Sinha R, *et al.* Toric intraocular lens versus monofocal intraocular lens implantation and photorefractive keratectomy: A randomized controlled trial. *Am J Ophthalmol* 2015;160:479-86.e2.
  6. Nanavaty MA, Bedi KK, Ali S, Holmes M, Rajak S. Toric intraocular lenses versus peripheral corneal relaxing incisions for astigmatism between 0.75 and 2.5 diopters during cataract surgery. *Am J Ophthalmol* 2017;180:165-77.
  7. Spadea L, Giovannetti F. Main complications of photorefractive keratectomy and their management. *Clin Ophthalmol* 2019;13:2305-15.
  8. Kim MH, Chung TY, Chung ES. Long-term efficacy and rotational stability of AcrySoftoric intraocular lens implantation in cataract surgery. *Korean J Ophthalmol* 2010;24:207-12.
  9. Waltz KL, Featherstone K, Tsai L, Trentacost D. Clinical outcomes of TECNIS toric intraocular lens implantation after cataract removal in patients with corneal astigmatism. *Ophthalmology* 2015;122:39-47.
  10. Ma JJ, Tseng SS. Simple method for accurate alignment in toric phakic and aphakic intraocular lens implantation. *J Cataract Refract Surg* 2008;34:1631-6.
  11. Till JS, Yoder PR Jr, Wilcox TK, Spielman JL. Toric intraocular lens implantation: 100 consecutive cases. *J Cataract Refract Surg* 2002;28:295-301.
  12. Cha D, Kang SY, Kim SH, Song JS, Kim HM. New axis-marking method for a toric intraocular lens: Mapping method. *J Refract Surg* 2011;27:375-9.
  13. Felipe A, Artigas JM, Díez-Ajenjo A, García-Domene C, Alcocer P. Residual astigmatism produced by toric intraocular lens rotation. *J Cataract Refract Surg* 2011;37:1895-901.
  14. Mencucci R, Giordano C, Favuzza E, Gicquel JJ, Spadea L, Menchini U. Astigmatism correction with toric intraocular lenses: Wavefront aberrometry and quality of life. *Br J Ophthalmol* 2013;97:578-82.
  15. Webers VSC, Bauer NJC, Visser N, Berendschot TTJM, van den Biggelaar FJHM, Nuijts RMMA. Image-guided system versus manual marking for toric intraocular lens alignment in cataract surgery. *J Cataract Refract Surg* 2017;43:781-8.
  16. Jaworski M, Wyględowska-Promieńska D, Jaworski P, Jaskot K, Bieda R, Packard R. Comparison between using INTEGRA and manual method in determining axis for intraocular lens implantation: Preliminary retrospective study. *Medicine (Baltimore)* 2020;99:e18582.
  17. Kim EC, Hwang KY, Lim SA, Yi R, Joo CK. Accuracy of toric intraocular lens implantation using automated vs manual marking. *BMC Ophthalmol* 2019;19:169.
  18. Varsits RM, Hirnschall N, Döllner B, Findl O. Evaluation of an intraoperative toric intraocular lens alignment system using an image-guided system. *J Cataract Refract Surg* 2019;45:1234-8.
  19. Patel CK, Ormonde S, Rosen PH, Bron AJ. Postoperative intraocular lens rotation: A randomized comparison of plate and loop haptic implants. *Ophthalmology* 1999;106:2190-5; discussion 2196.
  20. Prinz A, Neumayer T, Buehl W, Vock L, Menapace R, Findl O, *et al.* Rotational stability and posterior capsule opacification of a plate-haptic and an open-loop-haptic intraocular lens. *J Cataract Refract Surg* 2011;37:251-7.
  21. White papers, Eyecryl Toric Intraocular Lens, Biotech Vision Care.
  22. Chen Y, Cao Q, Xue C, Huang Z. Comparison of two techniques for toric intraocular lens implantation: Hydro implantation versus ophthalmic viscosurgical devices. *BMC Ophthalmol* 2018;18:109.
  23. Chang DF. Early rotational stability of the longer Staar toric intraocular lens: Fifty consecutive cases. *J Cataract Refract Surg* 2003;29:935-40.
  24. Sun XY, Vicary D, Montgomery P, Griffiths M. Toric intraocular lenses for correcting astigmatism in 130 eyes. *Ophthalmology* 2000;107:1776-81; discussion 1781-2.
  25. Ribeiro FJ, Ferreira TB, Relha C, Esteves C, Gaspar S. Predictability of different calculators in the minimization of postoperative astigmatism after implantation of a toric intraocular lens. *Clin Ophthalmol* 2019;13:1649-56.
  26. Li S, Li X, He S, Zheng Q, Chen X, Wu X, *et al.* Early postoperative rotational stability and its related factors of a single-piece acrylic toric intraocular lens. *Eye (Lond)* 2020;34:474-9.

Supplementary file 1: Surgical video showing the technique of loading and implantation of the Eyecryl Toric IOL in the RE of one of the study participants with pre-existing astigmatism of 1.5 D.